

Case report

Postoperative Treatment Streptococcus B Perianal Abscess with Topical Antimicrobial: A Case Report

John Lawlor, DPM

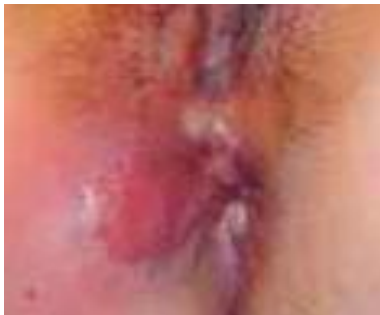ABSTRACT

We here report a case of a 51-year-old female with a perianal abscess. The abscess was found to be secondary to a transsphincteric fistula. The post-operative wound measured 5.3cm x 1.4 cm x 3.3 cm. The wound was packed with CurX treated packing strips. We found that topical CurX anti-microbial treatment was successful in allowing for rapid granulation and subsequent wound closure in a reduced time frame. We attribute these results to CurX's non-cytotoxic, anti-microbial properties.

1. Introduction

A 51-year-old woman was admitted for the management of a perianal abscess. The patient had a history of a prior perianal abscess 6 months previously and an iodine allergy. The prior abscess had been treated via bedside I&D and oral antibiotics. With the recurrence of infection, concern for the presence of an anal fistula arose and the patient was admitted under SIRS criteria for evaluation and intervention.

Pre-operative presentation

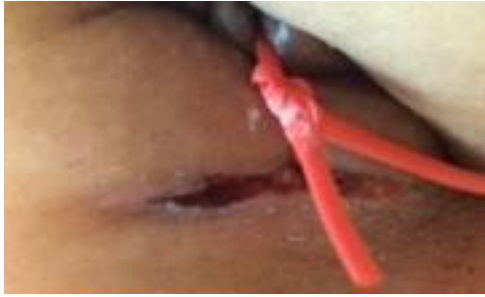

2. Method

Parenteral antibiotics were initiated, she was taken to the operating room for definitive treatment and placed under MAC anesthesia. An I&D was performed and exploration of the perianal space revealed a transsphincteric fistula as the source of the infection. A seton was initially placed to delineate the fistula. The fistula was subsequently repaired after the abscess was drained and washed out. Post-operatively a 3.3 cm deep soft tissue deficit remained.

In light of the patient's iodine allergy, the wound could not be treated with the standard betadine treated packing strips. Instead, the wound was packed with plain packing strips treated with CurX anti-microbial gel, gauze, and sealed with Tegaderm. The patient was discharged on oral antibiotics with instructions for daily dressing changes to be performed.

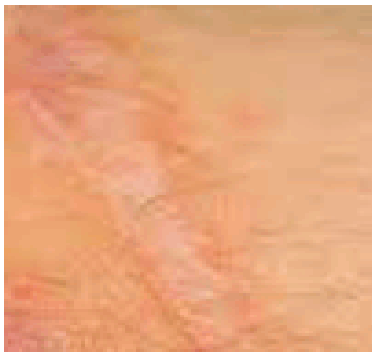
Intra-operative: Abscess drained and seton in place.



3. Results

Daily packing changes with the CurX treated packing strips were performed. By day 10 the soft tissue defect had fully granulated and packing was discontinued. The wound was subsequently dressed with a thin layer of CurX anti-microbial gel applied to the peri-wound area, with gauze and Tegderm to seal the peripheral edges. By day 17 wound closure had been achieved.

Day 17: wound closure



4. Discussion

The rate of granulation was markedly improved with the use of CurX Anti-microbial gel when compared with the rates of healing with betadine packing strips. Typical rates with betadine strips run in the 4-6-week range. It is theorized that the difference in rate of granulation is attributed to the difference in cytotoxic properties of the two products. Betadine, while being bactericidal, is cytotoxic to fibroblasts, which can delay healing. CurX gel lacks this limitation.

This case highlights the importance using of a non-cytotoxic, anti-microbial packing in the treatment of post-operative wounds. Ultimately, shorter duration of healing reduces the likelihood of opportunistic post-op infection and the use of a topical anti-microbial as an adjunctive treatment in conjunction with oral antibiotics provides a more ideal setting for healing to take place.